

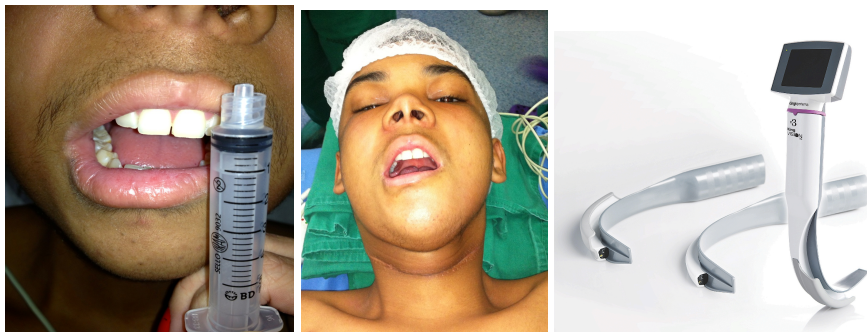
Tracheal intubation with King Vision in a patient with oral opening < 1 cm

Author(s): Márcio Pinho (presenter), Alexandre Bastos M., Cardoso Fontes L., Adolfo B. Pinto Calçada C.

Institute: Military Police Central Hospital, Dept of Anaesthesiology, Rio de Janeiro, Brazil

Background: The King Vision laryngoscope is a newly developed video laryngoscope (King Systems, Noblesville, IN, USA). There are few publications on this device¹. This report aims to describe the use of this video laryngoscope for tracheal intubation in a patient with multiple predictors of difficult airway².

Case report: Patient with cavum lymphoepithelioma with proposed surgical placement of tympanostomy and bilateral ventilation tube. After the previous surgery and adjuvant radiotherapy evolved with reduced mouth opening (< 1 cm), limitation of neck mobility and extension, Mallampati IV. Unavailability of fiberoptic intubation, we opted for the use of awake video laryngoscopy, despite the mouth opening < 1 cm. It was possible to introduce King Vision video laryngoscope standard blade (non-channeled blade) and perform tracheal intubation.



Discussion: It is important that anesthesiologists master different techniques for airway approach. Patients with impaired mouth opening can usually be intubated by fiberoptic endoscopy. Most modern video laryngoscopes need a mouth opening of at least 2.5 cm³. The objective here was to evaluate the possibility of video laryngoscopic tracheal intubation in a patient who had a mouth opening of 1 cm. Currently, King Vision is the only video laryngoscope having such a thin blade.

References:

1. Theiler L, Hermann K, Schoettker P et al. SWIVIT--Swiss video-intubation trial evaluating video-laryngoscopes in a simulated difficult airway scenario: study protocol for a multicenter prospective randomized controlled trial in Switzerland. *Trials*. 2013 Apr 4;14:94. 2. Law JA, Broemling N, Cooper RM et al; Canadian Airway Focus Group. The difficult airway with recommendations for management--part 2--the anticipated difficult airway. *Can J Anaesth*. 2013;60(11):1119-38. 3. Niforopoulou P, Pantazopoulos I, Demestihia T et al. Video-laryngoscopes in the adult airway management: a topical review of the literature. *Acta Anaesthesiol Scand*. 2010;54(9):1050-61.

Learning points: This case demonstrates that video laryngoscopy for tracheal intubation consists of an alternative tool for fiberoptic intubation even in cases of greatly reduced oral opening. It is important to master new techniques and test the limits taking into account the safety of patients. Further studies are needed to confirm and establish what are the limits of video laryngoscopy.

Additional information:

Patient aged 18 years, very cooperative. He received information about being patient with a difficult airway and agreed to be intubated awake. Conscious sedation with midazolam 2 mg, fentanyl 50 mcg and atropine 0.5 mg, then 10% lidocaine spray and lidocaine jelly in the mouth. After 5 min, we introduced the disposable non channeled blade without resistance. Tracheal tube n°.7.0 was introduced with a malleable metal stylet. Anesthesia induction immediately after intubation with Propofol 200 mg + Fentanyl 250 mcg IV + Atracurium 40 mg. Maintenance with 50% O₂ + Isoflurane (0.5 – 1 MAC). Extubation with the patient fully awake.

| King Vision Size 3 Blade | non-channeled (standard) | channeled |
|----------------------------|--------------------------|-----------|
| AP Height | 13 mm | 18 mm |
| Width (16mm at distal tip) | 26 mm | 29 mm |